

切片連結：[http://140.120.114.107/ivp\\_slide\\_view.php?id=1007](http://140.120.114.107/ivp_slide_view.php?id=1007)

切片名稱：Case4. WA104-259

Case 4. CSVP 2016-2878 (WA104-259, NPUST, L.F. Wang, Y.C. Li, C.C. Chang, C.N. Lin, M.T. Chiou)

Yellow-margined box turtle (*Cuora flavomarginata*), adult, female. The yellow-margined box turtle is housed in Pingtung Rescue Center since July 2015. She presented with weakness, dehydration and died following few days of supportive treatment. Postmortem examination revealed liver enlarge and became increasingly yellowish in color, also can see many white yellow fibrin covered on serosa.

### 病例討論：食蛇龜之多發性漿膜炎

Case report: Polyserositis in yellow-margined box turtle (*Cuora flavomarginata*)

王玲芳<sup>1</sup>、李伊嘉<sup>2</sup>、張志堅<sup>2</sup>、林昭男<sup>1,2</sup>、邱明堂<sup>1,2</sup>

Ling-Fang Wang<sup>1</sup>, Yi-Cha Li<sup>2</sup>, Chih-Chien Chang<sup>2</sup>, Chao-Nan Lin<sup>1,2</sup>, Ming-Tang Chiou<sup>1,2</sup>.

<sup>1</sup>Department of Veterinary Medicine, National Pingtung University of Science and Technology

(國立屏東科技大學獸醫學系)

<sup>2</sup>Animal Disease Diagnostic Center, College of Veterinary Medicine, National Pingtung University of Science and Technology (國立屏東科技大學動物疾病診斷中心)

本病例為一成年雌性食蛇龜，於 2015 年 7 月因非法走私被查獲而轉送屏東保育類野生動物收容中心收容。該批動物共有 1200 隻，收容時有部分龜群呈現虛弱及脫水的情形，死亡個體送檢至本校動物疾病診斷中心進行解剖。食蛇龜外觀無異狀，解剖病變可見體腔有少量清澈液體蓄積，肝臟色澤偏黃且漿膜面有多量黃白色纖維素附著，心外膜與消化道臟器之漿膜面亦有多量黃白色纖維素沾黏。組織病理學檢查可見肝小葉呈現瀰漫性壞死，漿膜層增厚且有多量纖維素沉積，高倍可見肝小葉壞死區有多量細胞壞死碎片。心臟心外膜有多量纖維素伴隨有單核炎症細胞浸潤。細菌培養結果並未分離到菌落。本病例最終診斷為食蛇龜之多發性漿膜炎。

關鍵字：食蛇龜，多發性漿膜炎

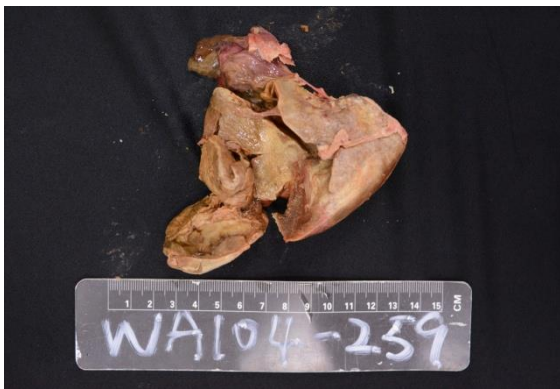

Fig. 1 Yellowish liver with white-yellow fibrin covered on serosa.

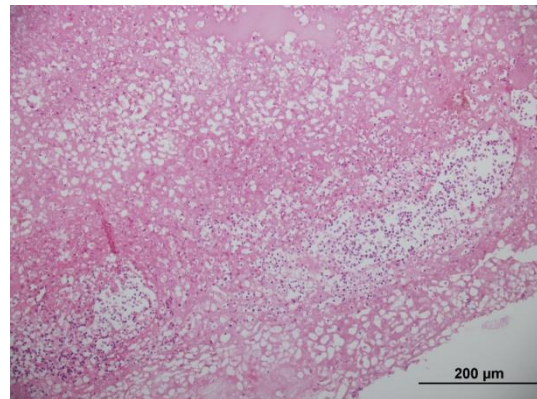


Fig. 2 Liver, fibrinopurulent serositis and diffuse necrosis. H&E stain (20X).